

Endoscopic resection of forehead osteomas

Andreas Foustanos^{a,1}, Harris Zavrvides^{b,*}

^a 32 Kifisias Avenue, Megaro "ATRINA", 151 25 Paradeisos Amarousiou, Athens, Greece

^b Pappas Court 3rd floor, 145 Kyrenias av. 2113, Aglantzia, Nicosia, Cyprus

Accepted 29 October 2006

Available online 5 December 2006

Abstract

Background: Endoscopic brow lift has become widely accepted as a procedure for restoring a youthful brow. Sometimes, a patient seeking a solution for rejuvenation of the upper third of the face may present other problems such as a forehead lesion. The authors describe their clinical experience in surgical endoscopic excision of forehead osteomas.

Patients and methods: In nine patients with a forehead osteoma, seeking for a solution in rejuvenating the upper third of the face, we performed a combination of endoscopic brow lift and endoscopic excision of the forehead osteoma. We also performed an endoscopic excision of a forehead osteoma in two patients that did not request any additional aesthetic face procedure.

Results: No complication and no recurrence have been reported. The aesthetic result satisfied the patients.

Conclusions: Endoscopic resection of a forehead osteoma offers sufficient, effective and safe access for dissection and suspension of the tissues released. It offers a superbly hidden scar and is well appreciated by the patients.

© 2006 The British Association of Oral and Maxillofacial Surgeons. Published by Elsevier Ltd. All rights reserved.

Keywords: Forehead osteoma; Endoscopic excision

Introduction

Endoscopic brow lift is a useful procedure because it results in limited tissue damage, decreased post-operative edema, shorter recovery and easily concealed surgical scars. Osteoma is a benign tumor, belonging to the bone-forming tumor group. It is classified into conventional classic osteoma, periosteal osteoma and medullary osteoma. The most common kind is the conventional classic osteoma and the majority of these occur in the craniomaxillofacial region. Generally, a simple excision is performed.¹ The authors performed excision of a forehead osteoma during an endoscopic brow lift in a series of nine patients showing hyperactive corrugator muscle, deep glabellar lines and brow ptosis requiring treatment. At the same time, face-lift (rhididectomy: skin dissection,

smasectomy) and blepharoplasty in the upper and lower lid on both eyes were performed. We also performed an endoscopic excision of a forehead osteoma in two patients that did not request any additional aesthetic face procedure. We describe our clinical experience in surgical endoscopic excision of forehead osteomas.

Patients and methods

Since January 2000, 11 patients aged 39–55 years, came to Iaso Hospital Plastic Surgery Department complaining of a subcutaneous tumor in the frontal region; they wanted the tumor to be removed with the scars well hidden (Table 1). Patients also presented rhytidosis; three patients with Grade I, and eight with Grade II rhytidosis, in need of an endoscopic brow lift, face-lift and blepharoplasty. The tumors had not increased in size over the past several years and they were not painful. The patients' medical histories were unremarkable. The patients denied any trauma to the site of the tumors,

* Corresponding author at: Patr. Gregoriou E' 17, Paphos 8011, Cyprus. Tel. +357 99595776; fax: +357 22 336500.

E-mail addresses: foustand@otenet.gr (A. Foustanos), HarrisZavrvides@hotmail.com (H. Zavrvides).

¹ Tel. +30 210 6825494/6851310; fax +30 210 6850606.

Table 1
Patient classification

| Patient | Age | Rhytidosis | Endoscopic resection of forehead osteoma | Endoscopic brow lift | Face lift | Blepharoplasty |
|---------|-----|------------|--|----------------------|-----------|----------------|
| 1 | 55 | Grade II | Yes | Yes | Yes | Yes |
| 2 | 50 | Grade II | Yes | Yes | Yes | Yes |
| 3 | 55 | Grade II | Yes | Yes | Yes | Yes |
| 4 | 54 | Grade II | Yes | Yes | Yes | Yes |
| 5 | 45 | Grade I | Yes | Yes | Yes | Yes |
| 6 | 54 | Grade II | Yes | Yes | Yes | Yes |
| 7 | 49 | Grade II | Yes | Yes | Yes | Yes |
| 8 | 46 | Grade II | Yes | Yes | Yes | Yes |
| 9 | 48 | Grade II | Yes | Yes | Yes | Yes |
| 10 | 39 | Grade I | Yes | No | No | No |
| 11 | 41 | Grade I | Yes | No | No | No |

recent acne or familial occurrence of skin lesions. Physical examination (round shaped mass, not soft, not mobile, and not tender) and skull X-rays revealed forehead osteoma. In two patients, even though they presented Grade I rhytidosis, they denied any additional aesthetic procedure except the frontal exostose resection.

Under general anesthesia, nine patients underwent an endoscopic brow lift. In order to provide hydro-dissection, the patient received sub-periosteal infiltration. According to the elevation vectors that we defined pre-operatively, we performed three incisions in the scalp. The 2–3 cm incisions were done posterior and parallel to the hairline. Two of them were lateral, each over the temporalis muscle and one medial. The endoscope used was an angle-vision 30-degree type arthroscope 4.0 mm in diameter with a light source. A sub-periosteal dissection was performed by frontalis muscle release, depressor supercillii muscle and corrugator muscles cutting. Simultaneously and under direct endoscopic vision, we performed the surgical resection of the frontal exosto-

sis utilizing a curved bone chisel. After the excision of the osteoma, the cranial surface was flattened with the bone chisel and the area was washed with saline. The extra-operative time was 4 min. The operation ended with a face-lift (rhididec-tomy: skin dissection and smasectomy) and with upper and lower blepharoplasty in both eyes. For the two patients not requiring additional aesthetic procedure, we only performed endoscopic excision of the forehead osteoma, under general anesthesia (Figs. 1–3).

Results

Intra-operatively, there were no surgical or aesthetic complications. Generally, no complication occurred and the patients had a normal post-operative period. There have been no haematomas, signs of nerve damage, vascular injuries, infections, or signs of alopecia. The histology specimen on the osteomas confirmed the clinical diagnosis. Follow up exami-

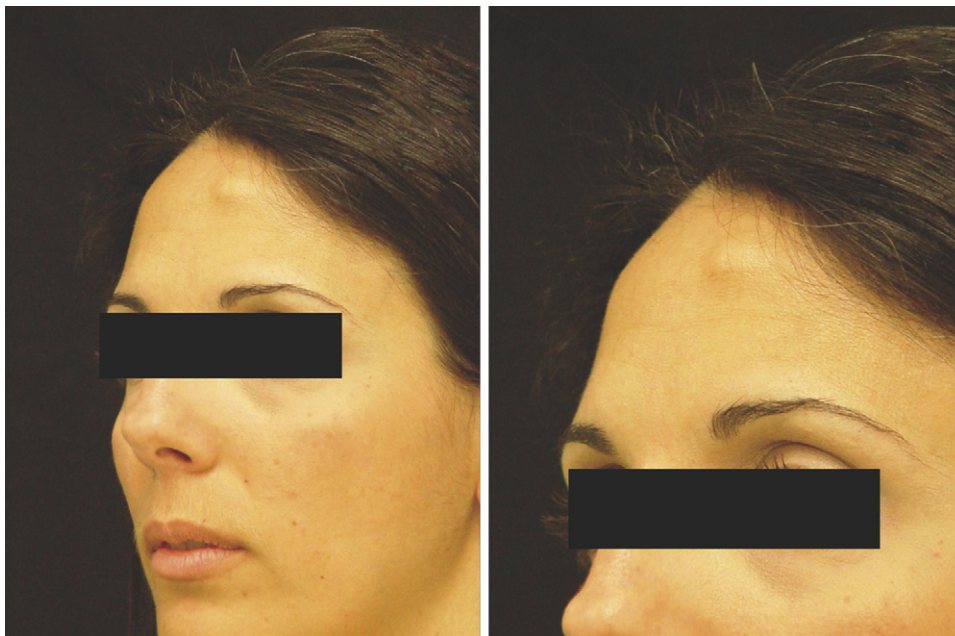

Fig. 1. A pre-operative view of the patient showing the forehead osteoma.

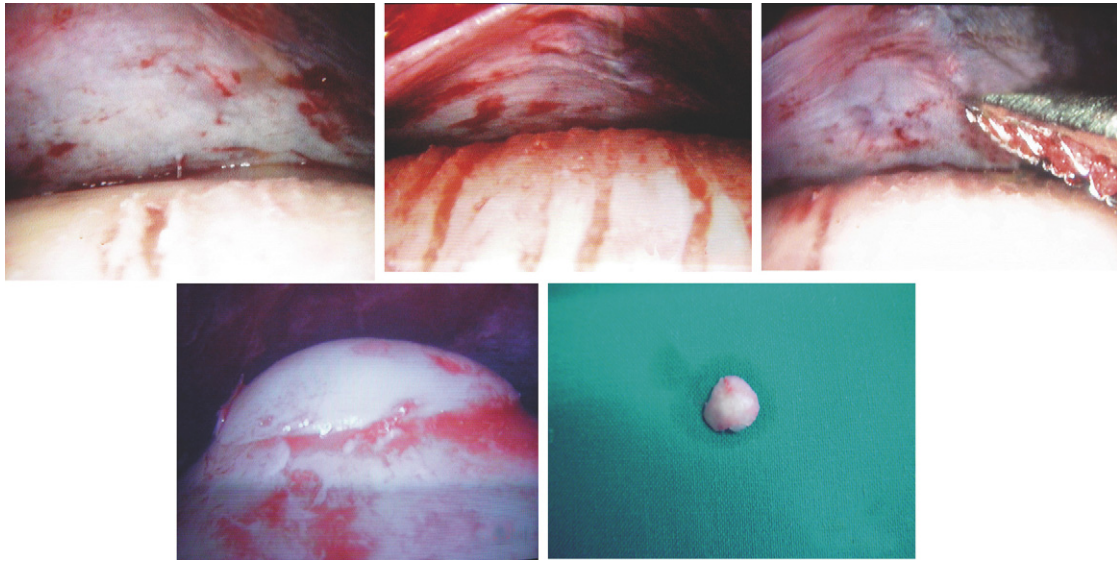


Fig. 2. The forehead osteoma under direct endoscopic vision and its surgical resection. The cranial surface is flattened with a bone chisel and the area is washed with saline.

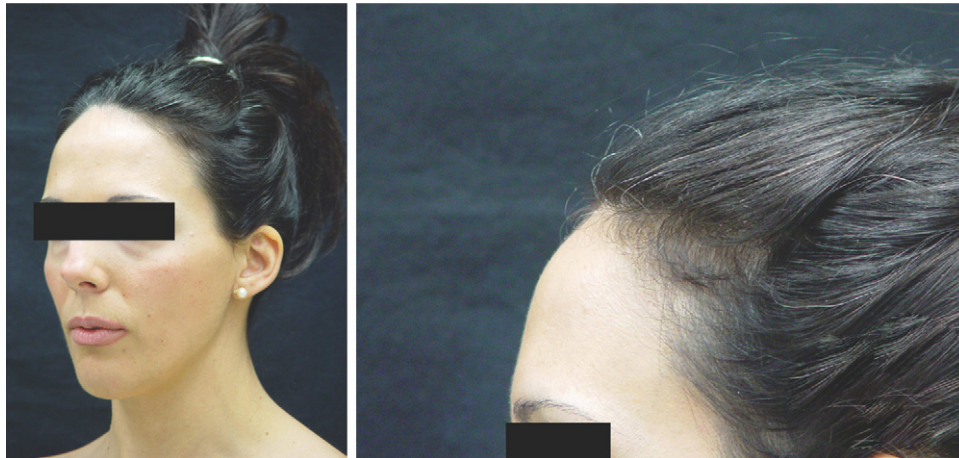

Fig. 3. Post-operative view of the patient.

nations were carried out in 1 month, 3 months, 6 months and yearly and showed no complication, no recurrence and the aesthetic result satisfied the patients.

Discussion

Endoscopic brow lift is a predictable procedure for rejuvenation of the upper third of the face with minimal complications. It has become an acceptable and reliable technique, alternative to the conventional technique or transcoronal browpexy.² The important advantages of an endoscopic brow lift are the shorter incisions, less tissue trauma, reduced scarring bleeding and edema, improved patient recovery, minimal alopecia or numbness and a generally superior aesthetic outcome because of the shortened incision line. Additionally, it allows earlier mobilization and shorter hospitalization.

Forehead osteoma is an uncommon benign bone tumor that causes aesthetic disfigurement and occasional pain.³ Direct excision of a forehead osteoma can produce a noticeable scar for a variety of reasons: a patient with a smooth forehead without many frown lines, a large mass necessitating an equally large incision, poor wound healing, predisposition to skin pigment changes, or an exaggerated healing response with hypertrophic scarring or keloid formation.^{3,4}

Endoscopic surgery has been used in the craniomaxillofacial region; endoscopic brow lift, face lift, frontal sinus operation, rhinoplasty, mandibular osteotomy and resection of sphenomastoid osteoma.¹ It has been reported that there is a reduction in incidence of infection and of post-operative haematomas in patients undergoing endoscopic procedures.⁵ Even though the endoscopic approach for resection of forehead osteomas is not new, our experience shows that it offers sufficient, effective and safe access for dissection and suspension of the tissues released. The endoscope provides direct

and magnified visualization allowing easy access for osteoma removal. The direct endoscopic vision involves no complications such as nerve damage, lymphatic or vascular injury.⁶

Endoscopic resection of forehead osteomas is a relative simple approach and easy to learn. It can be combined with other endoscopic procedures like endoscopic brow lift. This procedure is minimally invasive and contributes to an improved aesthetic appearance. Aesthetic considerations are important features in the craniomaxillofacial region. Especially for patients who are not willing to accept the risk of a prominent forehead scar. Endoscopic resection of forehead osteomas might be a useful tool in forehead osteoma excisions. It might be an alternative tool in an Oral and Maxillofacial Surgeon's and in a Plastic Surgeon's repertoire.

References

1. Onishi K, Maruyama Y, Sawaizumi M. Endoscopic excision of forehead osteoma. *J Craniofac Surg* 1995;**6**(6):516–8.
2. Ramirez OM. Endoscopic techniques in facial rejuvenation: an overview. *Aesthetic Plast Surg* 1994;**18**:141.
3. Edwart WH, Peter CW. Forehead osteoid osteoma: excision via a new approach. *Br J Plast Surg* 2000;**53**:711–3.
4. Cronin ED, Razura AR, Livingston CK, Katzen JT. Endoscopic approach of the resection of forehead masses. *Plast Reconstr Surg* 2000;**105**(7):2459–63.
5. Bostwick J, Evans EF, Nahai F, editors. *Endoscopic plastic surgery*. St Louis: Quality Medical Publishing; 1995. p. 6.
6. Chen CT, Huang F, Lin YT, et al. Endoscopically assisted removal of tumors in the frontal region. *Chang Gung Med J* 2004;**27**(10): 718–25.